

Three-dimensional Cryolipolysis for Submental and Lateral Neck Fat Reduction

Stavroula Rodopoulou, MD,
FEBOPRAS
Maria-Ioanna Gavala, MD
Evangelos Keramidas, MD,
FEBOPRAS

Summary: Median and lateral neck areas are quite challenging to improve. Three-dimensional cryolipolysis is a noninvasive technique for localized fat reduction. We investigated the efficacy and safety of the technique when applied to these areas. A prospective study of patients treated with one session of 3-dimensional (3D) cryolipolysis is performed. Clinical outcomes are assessed using caliper measurements, patient surveys, and independent, blinded plastic surgeons' photographic evaluation. The studies are conducted using a commercially available noninvasive medical device for 3D cryolipolysis. All patients received gentle massage of the treated areas for 3 minutes, and the final follow-up is after 3 months. Thirty-nine patients are enrolled in our study from June 2018 to December 2018. All 39 subjects received treatment on at least one intended area (median, right, and left lateral neck). Comparison of the pre- and posttreatment caliper measurements demonstrated a significant reduction of the treated areas at 3 months. Posttreatment, 82.05% of patients marked the results of fat reduction as exceptional or very improved, 12.82% as improved, 5.13% as no result, and 0% as worse. Improved patients and the blinded plastic surgeons noticed at these patients' groups a bonus tightening effect. No serious adverse reactions are observed; thus, 3D cryolipolysis considered as a safe and effective noninvasive localized fat reduction technique with an extra, almost regularly observed, tightening effect. (*Plast Reconstr Surg Glob Open* 2020;8:e2789; doi: [10.1097/GOX.0000000000002789](https://doi.org/10.1097/GOX.0000000000002789); Published online 29 April 2020.)

INTRODUCTION

Submental fullness is a rising aesthetic issue that has a profound impact on one's facial features. In the era of minimally invasive medical aesthetic procedures,¹ cryolipolysis has received much attention due to its proven safety, good patient tolerance, and efficacy.²⁻⁵ We present the results of 39 patients who underwent a 3-dimensional (3D) cryolipolysis solitary treatment cycle for the submental and lateral neck areas, using a novel, small, vacuum cryolipolysis cup applicator. To the best of our knowledge, this is the first office-based study concerning the entire neck area.

MATERIALS AND METHODS

Thirty-nine patients were enrolled in this study generated in our private practice between June 2018 and December 2018. Eligible participants demonstrated visible accumulation of submental and/or lateral neck fat, measured by

skinfold caliper of at least 1 cm, minor to moderate skin laxity, body mass index that ranged between 18.5 and 34.9 and agreed to maintain their body weight within 5% of the baseline during the study, and they were in general good health. All subjects provided written informed consent.

End Points

The safety end point of the device and/or procedure-related adverse effects were examined. Immediately after treatment, at 1 week and at 12 weeks post treatment, a clinical examination was performed and the patients filled in written questionnaires evaluating the pain and common symptoms.

Efficacy of treatment end points, between baseline and 12 weeks post treatment, were: statistically significant reduction of the skinfold caliper measurements, at least 80% correct identification of pre- and post treatment images assessed by a blinded panel of 3 independent board-certified plastic surgeons and at least 90% subject satisfaction rate using patient surveys.

Documentation

Before treatment and at 12-week follow-up visits, photographs were obtained with the subject's head in a neutral, sitting, and stable position. Caliper measurements were undertaken by the same physician, and an average of 3 different measurements was calculated. A transparent malleable film was also used to draw the

From the Kosmesis Aesthetic Plastic Surgery Center, Athens, Greece.

Received for publication January 9, 2020; accepted February 26, 2020.

Presented at the IMCAS Paris, January 31-February 2 2019, France

Copyright © 2020 The Authors. Published by Wolters Kluwer Health, Inc. on behalf of The American Society of Plastic Surgeons. This is an open-access article distributed under the terms of the [Creative Commons Attribution-Non Commercial-No Derivatives License 4.0 \(CCBY-NC-ND\)](https://creativecommons.org/licenses/by-nc-nd/4.0/), where it is permissible to download and share the work provided it is properly cited. The work cannot be changed in any way or used commercially without permission from the journal.

DOI: [10.1097/GOX.0000000000002789](https://doi.org/10.1097/GOX.0000000000002789)

Disclosure: The authors have no financial interest to declare in relation to the content of this article.

exact landmark points of the measurement and individuals' jawline to easily reuse it in a conventional manner in the follow-up visit.

3D Cryolipolysis Treatment

A commercially available device (CLATUU Alpha from Classys Inc, Seoul, South Korea, CE marked as medical device, Korean FDA, Thai FDA) was used in this study including a dual handpiece: a wing and a flat mini applicator that can function simultaneously. The adjustable parameters were suction, cooling, and duration. All 39 subjects received treatment on at least one intended area. For the purpose of this study, submandibular and carotid triangles were referred as lateral neck areas. Each treatment session included a minimum of 1 and a maximum of two 60 minutes cooling cycles, if applied in submental and both lateral neck areas. Treatment areas were marked and a disposable gel pad (CLATUU Matrix gel pad from Classys Inc, Seoul, South Korea, Korean FDA, Thai FDA) was used to fully cover and protect them, followed by application of the suction cup. Maximum suction pressure (30 Kpa) and maximum cooling temperature (-7°C) were then applied for 1 hour. A neck pillow and straps were used to stabilize the handpieces. At the end of the treatment, the area was manually massaged for 3 minutes, allowing the stiff tissue to gradually rewarm and regain its original shape.

RESULTS

Safety assessment revealed that 46.15% of patients mentioned minor pain during the procedure. Immediately after treatment, minor edema, redness, numbness, and tingling of the area were observed which, in most cases, resolved within hours or a few days. Other side effects included discomfort during therapy due to vacuum's cap weight that resolved in a few minutes. By the 12-week final evaluation visit, all side effects were self-resolved. Side effect profile considered to be safe and tolerable.

Skinfold caliper measurements were analyzed to calculate fat reduction (Table 1).

Submental areas showed a mean (SD) fat layer reduction of 7.4mm (2.4) or 35.3%. Concerning the right lateral neck areas, mean (SD) reduction was 5.5mm (1.1) or 30.51%, and for the left lateral neck areas, mean (SD) reduction reached 5.2mm (1.2) or 32.1%. MATLAB (from The Mathworks, Inc., Natick, Mass.) was used for all statistical analysis. Figures 1, 2 show a representative participant.

From the independent photographic review, the overall correct identification rate was 94.9% (111/117).

Patients' surveys according to the GAIS 5-point scale (Global Aesthetic Improvement Scale), showed that 82.05% considered the results of fat reduction as exceptional or very improved, 12.82% as improved, 5.13% as no result, and 0% as worse. An additional outcome is that 69.24% of patients marked the results of skin's tightening as exceptional or very improved, 20.51% as improved, 10.26% as no result, and 0% as worse. A very high percentage of patients (94.9%) would recommend 3D cryolipolysis to a friend and 92.3% found the procedure to be comfortable, generating for the whole study outcome a high subject satisfaction rate (93.6%). Thus, all safety and efficacy endpoints were satisfied.

DISCUSSION

Primary results of this study demonstrate neck's fat reduction and contouring improvement after a single hourly session of 3D cryolipolysis while providing safety, tolerability, and high patient satisfaction.

Previous studies investigated cryolipolysis in submental area using a device with an originally introduced 2-sided cooling plate technology of the vacuum cup applicators.⁵⁻⁸ In our study, another cryolipolysis device was used introducing a new patented 3D technology to treat the entire neck area. In 3D cryolipolysis that was investigated in this study, a 360° surrounding cooling effect (-7°C) was maintained three-dimensionally to the whole suctioned tissue (30 Kpa), for 1 hour. This may hypothetically lead to a more even "cooling shock" of the treated area, and therefore, a greater number of adipocytes cells were forced to apoptosis and permanent death, even after a solitary application.

A limitation of this study is the absence of a standardized method to quantify objectively fat reduction, except of the skinfold caliper measurements. Regarding skin tightening after 3D cryolipolysis treatment, it is a clinical finding, both from patients and plastic surgeons involved in the study judgment, but has not yet been confirmed through histologic examination. Skin firmness could be attributed probably to neocollagenesis stimulation and has been reported in previous case study reports.^{7,9,10} According to Carruthers et al⁹ as dermal fillers may stimulate neocollagenesis by stretching of the fibroblasts, similarly the mechanical stretching of the fibroblasts due to vacuum suction of the fatty bulge may be a contributing factor to neocollagenesis in cryolipolysis. Another factor might be the gradual fat elimination that might allow the skin to adjust more effectively in time and cover without excess, the resulted thinner fat pocket.

Table 1. Results with Pairwise Comparisons between Baseline and 12-week Follow-up

	Baseline	12-wk Follow-up	% of Submental Fat Reduction	Between Baseline and 12-wk Follow-up Difference in Means (SD)	P
Thickness of median (submental) and lateral neck fat (mm), mean (SD)					
Right (n = 11)	18.2727 (3.1652)	12.7273 (2.5334)	0.3051 (0.0455)	16.3029 (1.1282)	<0.01 (1.5664e-08)
Median (n = 38)	20.9211 (5.3594)	13.5000 (3.6373)	0.3530 (0.0633)	18.7921 (2.4343)	<0.01 (1.6198e-20)
Left (n = 9)	16.5556 (4.2164)	11.3333 (3.4641)	0.3212 (0.0630)	11.2351 (1.3944)	<0.01 (3.5356e-06)
Average	19.7414 (5.0837)	13.0172 (3.4666)	0.3390 (0.0627)	22.2629 (2.3002)	<0.01 (8.4677e-30)

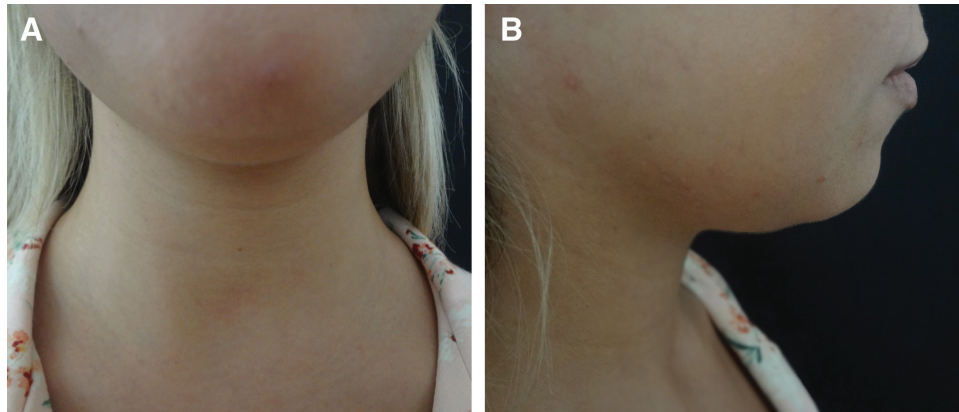


Fig. 1. Patient's baseline measurements: (A) submental 19 mm; (B) right lateral neck 19 mm; and (C) left lateral neck 17 mm (not shown).

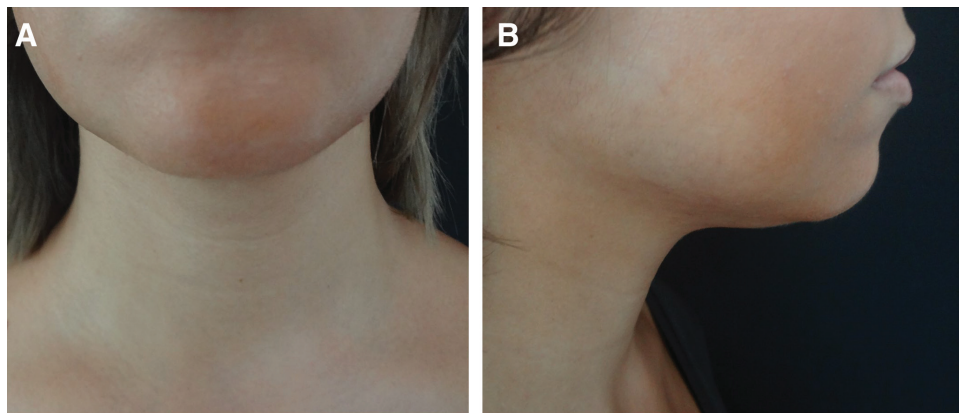


Fig. 2. Patient's measurements 3 months post treatment (A) submental 11 mm; (B) right lateral neck 12 mm; and (C) left lateral neck 12 mm (not shown).

Considering the treatment and consumables cost, it is quite affordable, which is an important factor in private practice both for patient's decision-making to undergo treatment and from the physician's point of view. Moreover, it should be noted that for this study population, the 3D cryolipolysis treatment was not free of charge, and, thus, the overall 94.9% satisfaction rate highlights the objectivity of their judgment.

CONCLUSION

The results of this study demonstrate that this novel 3D cryolipolysis treatment can lead not only to safe, well tolerated, and effective fat reduction, but also skin tightening in the entire neck area, following a single, 1-hour session.

Stavroula Rodopoulou, MD, FEBOPRAS
 Kosmesis Aesthetic Plastic Surgery Center
 Ethnikis Antistaseos 9-11
 Chalandri, Athens 15232, Greece
 E-mail: villyro@yahoo.com

REFERENCES

1. The American Society for Aesthetic Plastic Surgery Cosmetic Surgery National Data Bank Statistics for 2018.
2. Dierickx CC, Mazer JM, Sand M, et al. Safety, tolerance, and patient satisfaction with noninvasive cryolipolysis. *Dermatol Surg.* 2013;39:1209–1216.
3. Ingargiola MJ, Motakef S, Chung MT, et al. Cryolipolysis for fat reduction and body contouring: safety and efficacy of current treatment paradigms. *Plast Reconstr Surg.* 2015;135:1581–1590.
4. Derrick CD, Shridharani SM, Broyles JM. The safety and efficacy of cryolipolysis: a systematic review of available literature. *Aesthet Surg J.* 2015;35:830–836.
5. Kilmer SL, Burns AJ, Zelickson BD. Safety and efficacy of cryolipolysis for non-invasive reduction of submental fat. *Lasers Surg Med.* 2016;48:3–13.
6. Lipner SR. Cryolipolysis for the treatment of submental fat: review of the literature. *J Cosmet Dermatol.* 2018;17:145–151.
7. Bernstein EF, Bloom JD. Safety and efficacy of bilateral submental cryolipolysis with quantified 3-dimensional imaging of fat reduction and skin tightening. *JAMA Facial Plast Surg.* 2017;19:350–357.
8. Leal Silva H, Carmona Hernandez E, Grijalva Vazquez M, et al. Noninvasive submental fat reduction using colder cryolipolysis. *J Cosmet Dermatol.* 2017;16:460–465.
9. Carruthers J, Stevens WG, Carruthers A, et al. Cryolipolysis and skin tightening. *Dermatol Surg.* 2014;40(Suppl 1):S184–S189.
10. Stevens WG. Does cryolipolysis lead to skin tightening? A first report of cryodermadstringo. *Aesthet Surg J.* 2014;34:NP32–NP34.